

PROSTHODONTIC MANAGEMENT OF A PATIENT WITH UNILATERAL FACIAL PARALYSIS AFTER RESECTION OF VESTIBULAR SCHWANNOMA WITH A MODIFIED DESIGN OF CHEEK PLUMPER ON MAXILLARY COMPLETE DENTURE – A CASE REPORT**¹Dr. Sanjayagouda B. Patil, ²Dr. Sankar Madhavan, ³Dr. Abhijit Anil Tambe⁴ and Dr. Ashmi Sebastian**¹Professor and HOD, Department of Prosthodontics, Sri Hasanamba Dental College and Hospital, Vidyanagar, Hassan-573202, Karnataka, India.²Reader, Department of Prosthodontics, Sree Anjaneya Institute of Dental Science, Modakallur, Kozhikode, Kerala, India.³Assistant Professor, Department of Prosthodontics, MGV's KBH Dental College and Hospital, Panchvati, Nashik-422003, Maharashtra, India.⁴PG Student, Department of Prosthodontics, Sri Hasanamba Dental College and Hospital, Vidyanagar, Hassan-573202, Karnataka, India.***Corresponding Author: Dr. Sanjayagouda B. Patil**

Professor and HOD, Department of Prosthodontics, Sri Hasanamba Dental College and Hospital, Vidyanagar, Hassan-573202, Karnataka, India.

Article Received on 22/08/2018

Article Revised on 11/09/2018

Article Accepted on 02/10/2018

ABSTRACT

Acoustic neuroma or vestibular schwannoma is a benign tumor arising from the eighth cranial nerve in the internal auditory canal and cerebellopontine angle. The consequences of surgical removal of acoustic neuroma include hearing loss and facial palsy. Palliative treatment for permanent facial paralysis includes modifications of denture to provide support to cheek like padding for buccal flanges, spring loaded acrylic flanges and magnet retained cheek plumpers. The present case report deals with prosthodontic rehabilitation of a patient with unilateral facial paralysis after resection of acoustic neuroma.

KEYWORDS: Vestibular schwannoma; unilateral facial paralysis, maxillary complete denture, cheek plumper.**INTRODUCTION**

Acoustic neuroma, more properly known as vestibular schwannoma (Fig. 1) is a benign tumor arising from the eighth cranial nerve in the internal auditory canal and cerebellopontine angle.^[1-2] It is considered the most frequent among intracranial benign tumors - representing 90% of the ponto-cerebellar angle tumors and from 8 to 10% of all the cranial tumors. It is unilateral in about 95% of the cases.^[3] It is a slow-growing benign tumor that originates just inside the internal auditory meatus.^[4] As the tumor grows, it fills the cerebellopontine angle and inevitably produces displacement of the adjacent brain tissue involving the cerebellum, as well as the trigeminal, facial, glossopharyngeal and vagus nerves. The most common resulting neurological disorders are unilateral facial paralysis of the peripheral type, unilateral facial hyperalgesia, ipsilateral cerebellar ataxia, dysphonia, dysarthria and dysphagia. The increased intracranial pressure also causes headaches and vomiting.^[5] The care of patients with a vestibular schwannoma requires multidisciplinary teamwork.^[6]

The consequences of surgical removal of an acoustic neuroma include hearing loss and facial palsy.^[7] Facial

paralysis is considered as a disaster by many patients because of the cosmetic, functional and psychological disorders.^[8] Our society places on physical appearance and leads to isolation of patients who are embarrassed with their paralyzed face. There may be asymmetry of facial expression, drooling and difficulty with speech. The objective of the facial rehabilitation is to correct the functional and cosmetic losses of the patient. The primary cosmetic goals are to create balance and symmetry of the face at rest and to re-establish the coordinated movement of the facial musculature. The treating surgeon should be familiar with the variety of options available so that an individual plan can be developed based on each patient's clinical picture. The dental prosthesis can offer special protection after surgery and enhance oral rehabilitation.^[9-10]

Palliative treatment for permanent facial paralysis include, modifications of denture to provide support to cheek like padding for buccal flanges,^[11] spring loaded acrylic flanges^[12] and magnet retained cheek plumpers.^[13] The problems encountered during prosthodontic rehabilitation include uncontrolled flow of saliva, a mask-like expressionless appearance and cheek

biting. Establishment of the neutral zone in such patients is a challenge. The aim of the article is to describe the prosthodontic management of a patient with unilateral facial paralysis after resection of an acoustic neuroma.

CASE REPORT

A 50 year old male patient reported to the department of Prosthodontics, with the chief complaint of asymmetry of the face, difficulty in masticating food and speech. The patient presented with completely edentulous maxillary arch, partially edentulous mandibular arch and unilateral facial paralysis with the left side of the face. Patient's medical history revealed that he was diagnosed with acoustic neuroma of the left side for which he had under gone surgery twice once in 2006 and then in 2008. The unilateral facial paralysis of the left side was noted after the second surgery. At present the patient is not under any medication or treatment for the same.

An extraoral examination revealed asymmetry of face with loss of muscle bulk and facial weakness on the paralyzed side along with loss of sensation on the skin (Fig. 2a,2b). There was loss of transverse wrinkles of the forehead and drooping of eyebrows. There was inability to close/wink the eye, loss of nasolabial fold and drooping of the corner of the mouth on the affected side. The palpebral fissure was wider than that of the normal side due to un-opposed action of the levator palpebrae superioris. There was buccolabial insufficiency and commissural sag on the left side of the face. Pursing of the whistle was disturbed as the lips on the affected side could not move. The face was drawn to the right side during phonation with significant difficulty with the bilabial plosives (p,b), labiodentals and fricatives (f,v). The angle of the mouth remained motionless on the left side during smiling. There was no deviation of the mandible on opening and no signs or symptoms of angular stomatitis. According to House – Brackman^[14] (1985) classification his condition was classified as grade – V i.e. severe dysfunction – barely perceptible motion, asymmetry at rest, no movement of forehead, incomplete closure of the eye and slight movement of the mouth.

An intra oral examination revealed a completely edentulous maxillary arch with well-rounded residual ridge and partially edentulous mandibular arch (Kennedy's Class I). On protrusion the tongue deviated slightly towards the unaffected side (Fig. 3a,3b,3c), there was no impaired deglutition but there was altered taste sensation and lack of oral and pharyngeal sensation on the affected side. There were no signs or symptoms of salivary hypofunction. The patient was edentulous since 3 years and had no previous dentures constructed. The patient was not willing for implant supported prosthesis as he did not want to undergo any more surgical procedures. Thus, the treatment plan included fabrication of complete denture for the edentulous maxillary arch with an addition of acrylic bulk on the affected side to improve facial asymmetry and a distal extension mandibular partial denture by recording neutral zone.

For the edentulous maxillary arch, primary and secondary impressions were made using the standard technique and cast obtained.^[15] Functional impression technique was used to record the distal extension mandibular arch and cast poured in Type III dental stone (Power, J.K. Chemicals, India). The occlusal rims were constructed and jaw relations recorded taking care that the paralyzed side of the lip was carefully retracted to create symmetry on both sides. The neutral zone was recorded for the mandibular arch using a 3:7 eutectic mixture of medium fusing impression compound and low fusing green stick.^[16] An index was made in silicone putty to conform the buccal and lingual indices of the neutral zone. The eutectic mixture of medium fusing impression compound and low fusing green stick was removed and replaced with modeling wax. Recording of the centric relation was carried out by guidance prior to closing and swallowing which produces more accurate results, particularly in patients with neurological deficiencies.^[4]

The teeth were selected and arranged so as to provide the best esthetic and functional advantage. The mandibular posterior teeth were positioned in the recorded neutral zone and care taken to preserve the form of the polished surfaces (Fig.4a,4b,4c,4d). During the try-in an addition of wax bulk on the maxillary denture was carried out in accordance with Larsen et al^[11] to achieve a disto-superior tension on the vestibular fornix (Fig.5a). This bulk in the denture provides additional support to the cheek. The dentures were processed in the usual manner and dentures delivered with the necessary instructions (Fig 5b,5c).

The need for a second denture

The patient reported back to the Department of Prosthodontics with a dislodging maxillary complete denture and unsatisfied esthetics. The patient was re-evaluated for the esthetic component of the dentures. The left side of the face looked under supported even with an increase in the bulk of the denture using a disto-superior tension. The patient was asked for his willingness for the construction of a new denture with a modified technique. The patient agreed for the same and posted for a new set of dentures with a uniform tension from midline to the distobuccal pouch of the maxillary denture.

The entire denture construction procedure was repeated for the maxillary following the same steps as described earlier. During the try-in an addition of wax bulk on the maxillary denture was carried out to provide uniform tension on the cheek from midline to the distobuccal region. The patient was quite happy with the improved support on the affected side of the face. The dentures were processed and delivered (Fig.6). There was marked improvement the patient acceptance of the new dentures (Fig. 7). The patient was monitored on a regular basis and continues to be happy with his new prosthesis.

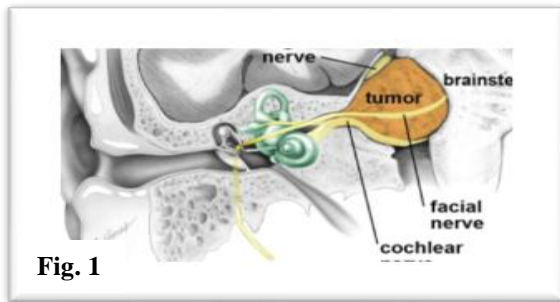


Figure 1: Schematic diagram of Acoustic neuroma (Vestibular Schwannoma).



Figure 2a,2b: Extraoral examination reveals asymmetry of face with loss of muscle bulk and facial weakness on the paralyzed side.

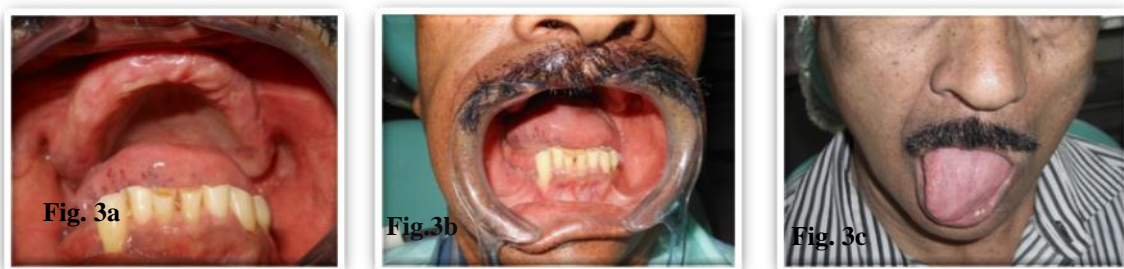

Fig. 3a,3b,3c: Intraoral examination of the patient showing edentulous maxillary arch, partially edentulous mandibular arch and tongue deviation towards unaffected side during protrusion.

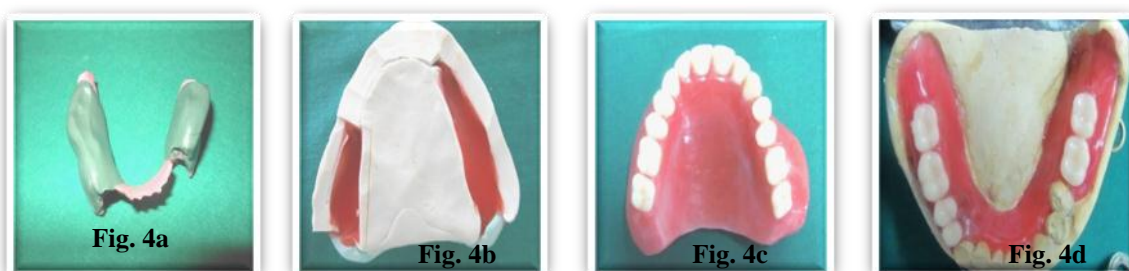


Figure 4a,4b,4c,4d showing neutral zone recorded for mandibular arch along with teeth arrangement.

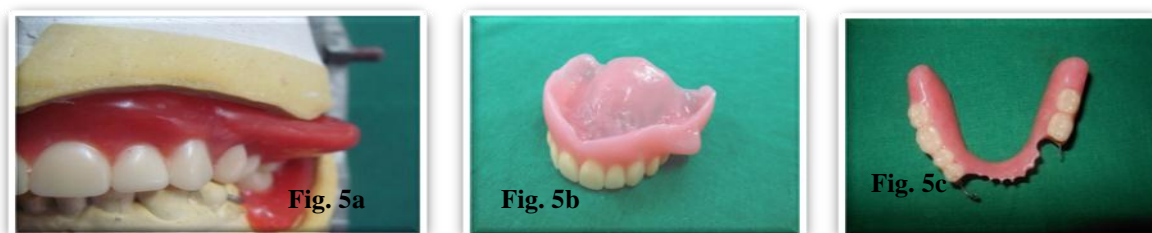

Figure (5a) showing addition of wax bulk in maxillary denture during try-in (in accordance with Larsen et al)^[11], processed maxillary complete denture prosthesis (5b) and mandibular removal partial denture (5c).

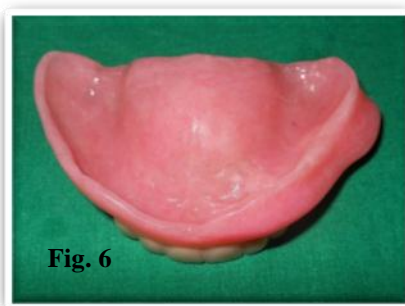

Fig. 6

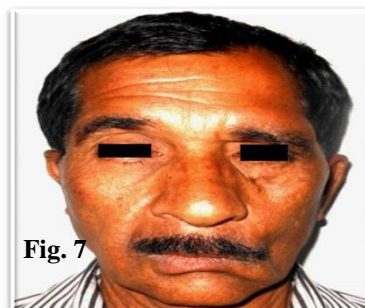


Fig. 7

Figure 6 and 7 showing processed denture with bulk on maxillary denture tapering towards the midline and post-op profile of the patient with improved support on the affected side of the face with uniform bulk from midline to the disto-buccal region respectively.

DISCUSSION

Unilateral paralysis of the facial muscles is the result of lower motor neuron lesions. Surgical approaches to improve effects of permanent facial paralysis have been described^[17] such as muscle trans-positioning and free muscle transfer. But in many of the patients due to the age and depleting health condition, the surgery is contraindicated or unsuccessful. Neuro-muscular function and coordination are foundation for successful and stable prosthesis. Drooping of the corner of the mouth, food accumulation in the vestibule and unsupported cheek on the affected side of the face pose problems in oral rehabilitation of such patients.

Authors have advocated padding of the buccal flanges, spring loaded acrylic flange extensions etc. to support the facial musculature.^[12,18] The stability of the denture is affected by fit of the impression surface, direction and magnitude of forces transmitted through polished surface. Hence in unilateral facial paralysis patient, it is essential to record neutral zone because of imbalanced forces generated by unaffected and affected side causing instability in dentures. In the present case report, the facial asymmetry could be improved with the use of removable prostheses that supported the paralyzed facial musculature. Larsen *et al*^[11] have advocated the use of disto-superior tension on the vestibular fornix to achieve an improved support. But we found in the present case that an application of uniform tension on the cheek from midline to the distobuccal region provided better support to the cheek and hence an improved esthetics and better acceptance of the prosthesis by the patient. The problem of cheek biting was solved by the acrylic extension, which supported the cheeks on the affected side.

Only a limited amount of tension can be applied on the labial vestibular region by the addition of acrylic bulk without traumatizing the tissues. Thus certain amount of labial commissural sag was unavoidable. It was observed that by supporting the paralyzed side with the prosthesis, less resistance was encountered by the muscles on the unaffected side during speech. Thus the patient's ability to produce the bilabial plosive sounds (p, b) and labio-dental fricative sounds (f, v) improved significantly.

Clinical Implications

Conservative management of edentulous patients with facial can be carried out with simple modifications in the conventional treatment procedure, to improve facial symmetry, restore the oral function and esthetics.

REFERENCES

1. Lanser MJ, Sussman SA, Frazer K. Epidemiology, pathogenesis, and genetics of acoustic tumors. *Otolaryngol Clin North Am*, 1992; 25: 499–520.
2. Sanosi A, Fagan PA, and Biggs ND. Conservative Management of Acoustic Neuroma. *Skull Base*, May, 2006; 16(2): 95–100.
3. Corona AP, Oliveira JC, Souza FP, Santana LV, Rêgo MA. Risk factors associated with vestibulocochlear nerve schwannoma: systematic review. *Braz J Otorhinolaryngol*, 2009; 75(4): 593-615.
4. Karkazis HC. Prosthodontic management of a patient with neurological disorders after resection of an acoustic neurinoma: A clinical report. *J Prosthet Dent*, 2002; 87: 419-22.
5. Bateman N, Nikolopoulos TP, Robinson K, O'Donoghue GM. Impairments, disabilities, and handicaps after acoustic neuroma surgery. *Clin Otolaryngol*, 2000; 25: 62-65.
6. Saeed SR, Suryanarayanan R, Dezso A and Ramsden RT. Vestibular schwannoma management: current practice amongst UK otolaryngologists--time for a national prospective audit. *Ann R CollSurg Engl*, 2006; 88(5): 490-95.
7. de Keyser J, Bruyland M, Demol P, Klaes R, Ebinger G. Sudden hearing loss and facial palsy at the contralateral side following acoustic tumour removal. *J Neurol Neurosurg Psychiatry*, 1983; 46(7): 687.
8. Mackenzie I. Consequences of removing an acoustic neuroma by conventional methods. *Proc R Soc Med.*, 1965; 58(12): 1071-73.
9. Whitaker EJ, Luchetti CJ. Treating the oral sequelae of an acoustic neuroma. *J Am Dent Assoc*, 1996; 127(2): 231-33.
10. Fogg RA, Radell MH. A removable oral prosthetic appliance for Bell's palsy: report of case., 1977; 94(6): 1169-72.

11. Larsen SJ, Carter JF, Abrahamian HA. Prosthetic support for unilateral facial paralysis. *J Prosthet Dent*, 1976; 35(2): 192-201.
12. Fickling BW. Buccal sulcus supports for facial paralysis. *Br Dent J.*, 1951; 90(5): 115-17.
13. Riley MA, Walmsley AD, Harris IR. Magnets in prosthetic dentistry. *J Prosthet Dent.*, 2001; 86(2): 137-42.
14. House JW and Brackmann DE. Facial nerve grading system. *Otolaryngol Head Neck Surg*, 1985; 93: 146-147.
15. Winkler S. Essentials of complete denture prosthodontics. 2nd ed. St Louis: Ishiyaku Euro America, 1994; 88: 202.
16. Cagna DR, Massad JJ and Schiesser FJ. The neutral zone revisited: From historical concepts to modern applications. *J Prosthet Dent*, 2009; 101: 405-412.
17. Baker DC, Conley J. Facial nervegrafting: a thirty year retrospective review. *Clin Plast Surg*, 1979; 6(3): 343-360.
18. Sather AH and Williams HL. Dental appliances of value in Bell's palsy. *Arch Otolaryngol*, 1963; 78: 210-12.