

**ELONGATED STYLOID PROCESS AND ANATOMICAL IMPLICATIONS FOR
EAGLE'S SYNDROME****Dr. Bheem Prasad^{1*}, Dr. Padamjeet Panchal²**^{1,2}Assistant Professor, Department of Anatomy, All India Institute of Medical Sciences, Phulwari-Sharif, Patna, Bihar, India.***Corresponding Author: Dr. Bheem Prasad**

Assistant Professor, Department of Anatomy, All India Institute of Medical Sciences, Phulwari-Sharif, Patna, Bihar, India.

Article Received on 23/03/2017

Article Revised on 13/04/2017

Article Accepted on 03/05/2017

ABSTRACT

Eagle's Syndrome is a condition of an elongated styloid process or ossification of the stylohyoid ligaments. It may cause throat pain, otalgia, foreign body sensation, difficulty in swallowing, etc. In adults the styloid process is usually 20 - 30 mm but if it is more than 30 mm it is called as elongated styloid process. It can be diagnosed by a detailed history, physical examination and radiological investigation. The aim of the present study was to determine the average length of the styloid process in the dry human skulls. This study was conducted on 50 dried adult human skulls of the Department of Anatomy, All India Institute of Medical Sciences, Patna. The length of the styloid process was measured from its base to the tip of the styloid process by a Digital Vernier Caliper. Among the 50 dry skulls, the elongated styloid process was unilaterally in two skulls. The maximum length of styloid process was 35.59 mm on the right side, whereas the left side styloid process was a normal length. The average length of the styloid process on left side was 21.01 ± 6.67 mm, whereas on the right side was 21.20 ± 6.97 mm. An awareness of the Eagle's syndrome is important to all health professionals who are involved in the diagnosis and treatment of head and neck pain management.

KEYWORDS: Eagle's syndrome, Elongated styloid process, Ossification, skull, Stylohyoid ligament, styloid process.

INTRODUCTION

The styloid process of temporal bone is a long, cylindrical and cartilaginous bone. It is attached to the base of the skull and extends downwards, forward and medially narrowing toward the tip.^[1] The tip of the styloid process is related to the internal and external carotid arteries. The enlarged styloid process is more common in the rural Indian population which is possibly due to dietary habits.^[2,3] The styloid process range from 20 to 30 mm in length, which is hardly palpable. This process is normally composed of dense connective tissue in adults. When it is more than 30 mm it is called as Eagle's Syndrome. This syndrome was first described by Pietro Marchetti in 1652 and Eagle term was coined by Watt W. Eagle in 1937.^[4,5] Anomalous styloid processes occur commonly in older patients due to result in the deposition of calcium salts into the ligaments and processes.^[6] The purpose of the present study was to evaluate the average length of the styloid process in the dry human skulls present in the department.

MATERIALS AND METHODS

This study was conducted on 50 dried adult human skulls of unknown age and sex obtained from the Department of Anatomy, All India Institute of Medical Sciences, Patna, Bihar. All dry skulls were regular in shape,

without any deformities. Broken and damaged skulls were excluded from this study. Each skull was examined carefully for the length of the styloid process. The length of the styloid process was measured from its base to the tip of the styloid process by a Digital Vernier Caliper (Aero space, Model No. DVCA150). Skulls with elongated styloid process were photographed.

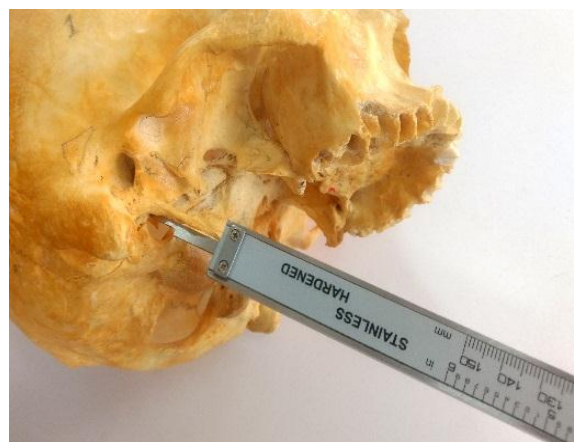

Fig. 1: Measurement of styloid process in dry human skull.

RESULT

Among the 50 dry skulls, the elongated styloid process was unilateral in 2 skulls. The details of elongated

styloid process are mentioned in Table 1 and 2. The findings are shown in the figure 2.

Table: 1 Measurement of length (in mm) of total, normal and elongated styloid process.

Sr. No.	Styloid process	No. of skulls	Right Length (Mean±SD)	Left Length (Mean±SD)
1	Normal (<30 mm)	48	20.66±6.58	20.69±6.62
2	Elongated(>30 mm)	2	33.88±2.41	28.54±1.04
3	Total	50	21.20±6.97	21.01±6.67

Table 2: Length of elongated styloid process

Sr. No.	No. of skull	Right Length (in mm)	left Length (in mm)
1	Skull A	32.17	27.80
2	Skull B	35.59	29.28

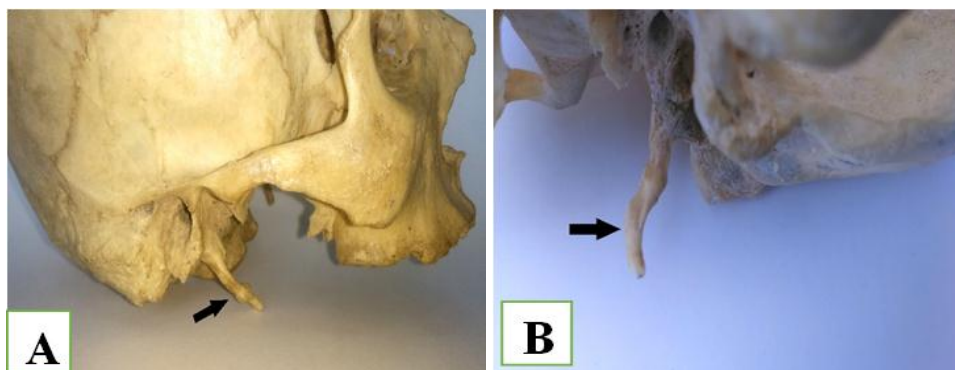


Fig: 2 Photographs (A & B) showing unilateral elongated styloid process.

DISCUSSION

Elongated styloid process is a rare entity, which is not commonly found in clinical practice. Eagle's syndrome is caused by elongated styloid process that is associated with a wide variety of symptoms. Pain is a possible symptom of Eagle's syndrome. It is usually associated with throat pain, foreign body sensation in the pharynx, dysphagia and facial pain. It can also cause transient ischemic attacks, tongue pain, alterations in taste, vocal changes, and facial paresthesia. The prevalence of this syndrome is 4% of the general population.^[7]

Patients with elongated styloid process occurs usually in older than 30 years and it is rarely found in younger. The elongated styloid process can be unilaterally or bilaterally. The unilateral elongated styloid process is more common. Eagle syndrome or styloid or stylohyoid syndrome is the symptomatic elongation of the styloid

process or calcification of the stylohyoid ligament complex.^[8] Watt W. Eagle reported that the normal length of styloid process is approximately 25.0-30.0 mm. He also found that the severe symptom of atypical facial pain is correlated with elongated styloid process.^[9] Promthale et al. reported that the mean length of styloid process was 24.12±7.28mm.^[10]

Yetiser et al. (1997) found that the anterior angulation and the length of the styloid process correlated with the symptoms of Eagle syndrome.^[11] According to That et al. (2000) the length of styloid process in Indian subjects varied from 8 mm to 24 mm (Left side) and the average length of styloid process on the left and right side were 15.2 mm and 15.9 mm respectively.^[12] Frommer stated that the direction and curvature of styloid process are more important than its length in causing symptoms.^[13]

Table: 3 The frequency of elongated styloid process in different studies

Sr. No.	Author(s)	Year	Type of cases	Number of cases	Frequency (%)
1	Correll et al. ^[14]	1979	Panoramic radiographs	1771	18.2
2	Lengele and Dhem ^[15]	1988	Skulls	246	29
3	Rath et al. ^[16]	1991	Skulls	232	4
4	Bozkir et al. ^[17]	1999	Panoramic radiographs	200	4
5	Promthale et al. ^[10]	2012	skulls	326	18.40
6	Chauhan et al. ^[18]	2014	skulls	110	14.54
7	Diwan et al. ^[19]	2016	Skulls	70	10
8	Present study	2017	skulls	50	4

The present study showed that out of 50 skulls, 2 (4%) skulls had length of styloid process more than 30 mm, which is in support with the study of Rath *et al.* and Bozkie *et al.*

The normal styloid process usually not palpable. The diagnosis of Eagle Syndrome can be confirmed clinically by clinical manifestation, careful intraoral palpation in the tonsillar fossa, radiological findings and by lidocaine infiltration test.^[7]

CONCLUSION

An awareness of pain syndromes related to the styloid process is important to all physicians and dentist involved in the diagnosis and treatment of head and neck pain management. Clinicians must be aware of the morphology of the styloid process for proper diagnosis and management of Eagle's syndrome.

REFERENCES

1. Standring S. In Gray's Anatomy. The Anatomical basis of clinical practice. External and middle ear. 41st Ed. Elsevier, Churchill Livingstone, Edinburgh, London, 2016; 626.
2. Fini G, Gasparini G, Filippini F, Becelli R, Marcotullio M. The long styloid process syndrome or Eagle's syndrome. *Journal of Cranio-Maxillofacial Surgery*, 2000; 28: 123-127.
3. Yadav SP, Chanda R, Gera A, Yadav RK. Stylalgia: An Indian perspective. *J Otolaryngol*, 2001; 30: 304-06.
4. Murtagh, R.D., Caracciolo, JT, Fernandez, G. CT Findings Associated with Eagle Syndrome. *American Journal of Neuroradiology*, 2001; 22, 1401-1402.
5. Thot B, Revel S, Mohandas R, Rao AV, Kumar A. Eagle Syndrome. *Anatomy of the styloid process. Indian J Dent Res.*, 2000; 11: 65-70.
6. Breault M.R. Eagle's syndrome: review of the literature and implications in craniomandibular disorders. *J. Craniomandibular Pract*, 1986; 4(4): 323-337.
7. Piagkou M, Anagnostopoulou S, Kouladouros K, Piagkos G. Eagle's syndrome: a review of the literature, Jul, 2009; 22(5): 545-58.
8. Ceylan A., Köybaşıoğlu A., Celenk F., Yilmaz O., Uslu S. Surgical treatment of elongated styloid process: experience of 61 cases. *Skull Base*, 2008; 18(5): 289-295.
9. Eagle WW. Elongated styloid process: symptoms and treatment. *AMA Arch Otolaryngol*, Feb, 1958; 67(2): 172-6.
10. Promthale TV, Chaisuksuni V, Wapinhasmit TR. Anatomical consideration of length and angulation of the styloid process and their significances for eagle's syndrome in thais. *Siriraj Med J*, 2012; 64(1): s30-s33.
11. Yetiser S, Gerek M., Ozkaptan Y. Elongated styloid process: diagnostic problems related to symptomatology. *Cranio*, 1997; 15:236- 41.
12. That B, Revel S, Mohan Das R, Rao AV, Kumar A. Eagle's Syndrome: Anatomy of styloid process. *Indian J Dent Res.*, 2000; 11: 65-70.
13. Frommer J. Anatomic variations in the stylohyoid chain and their possible clinical significance. *Oral Surg Oral Med Oral Pathol*, 1974; 38: 659-667.
14. Correl RW, Jensen JL, Taylor JB, Rhyne RR. Mineralisation of the stylohyoid-stylomandibular ligament complex. A radiographic incident study. *Oral Surg Oral Med Oral Pathol*, 1979; 48: 286-91.
15. Lengele BG, Dhem AJ. Length of the styloid process of the temporal bone. *Arch Otolaryngol Head Neck Surg.*, 1988; 114: 1003-1006.
16. Rath G, Anand C. Abnormal styloid process in a human skull. *Surg Radiol Anat*, 1991; 13: 227-229.
17. Bozkir MG, Boga H, Dere F. The evaluation of elongated styloid process in panoramic radiographs in edentulous patients. *Turk J Med Sci.*, 1999; 29: 481-485.
18. Chauhan PR, Rathod TV, Jain AA, Patel MD, Trivedi DJ, Singel TC. Study of Elongated Styloid Process in Dry Human Skulls and its Clinical importance. *Global Journal for research analysis*, 2014; 3(11): 82.
19. Diwan RK, Rani A, Pankaj AK, Verma RK, Chopra J, Kumar N. Study of elongated styloid process in dry human skulls of north Indian population. *Journal of dental and medical sciences*, 2016; 15(11): Ver 1: 66-68.