

ULCER HEALING EFFECT OF ETHANOLIC EXTRACT OF UNRIPE *MUSA PARADISIACA* ON ASPIRIN INDUCED GASTRIC ULCERATION IN ADULT WISTAR RATS**Nweke Elizabeth Obioma¹, Opara Julia Kelechi^{2*}, Nweke Tochukwu Miracle¹, Ewa Ogonnaya³, Ndibe Offor Sunday¹**¹Department of Anatomy, Faculty of Basic Medical Sciences, Chukwuemeka Odumegwu Ojukwu University, Anambra State, Nigeria.²Department of Anatomy, Faculty of Basic Medical Sciences, Gregory University Uturu, Abia State, Nigeria.³Department of Biochemistry, College of Medicine and Health Science/Gregory University, Uturu, Nigeria.***Corresponding Author: Opara Julia Kelechi**

Department of Anatomy, Faculty of Basic Medical Sciences, Gregory University Uturu, Abia State, Nigeria.

Article Received on 02/10/2018

Article Revised on 23/10/2018

Article Accepted on 13/11/2018

ABSTRACT

This study investigated the ulcer healing potential of unripe *Musa paradisiaca* fruit on aspirin induced gastric ulcer. Twenty five (25) adult wistar rats were divided into five groups (A, B, C, D and E) of five rats each. Group A was administered with 2ml/kg distilled water orally (normal control), Group B was administered with 300mg/kg b.w aspirin orally (negative control) Groups C-E were administered with 300mg/kg aspirin orally prior to treatment with 100, 500 and 1000mg/kg b.w orally respectively. The animals were sacrificed by cervical dislocation and ulcer index was determined on harvested stomach tissue. Oral administration of aspirin caused a significantly high ulcer index (1.53 ± 0.46). However, treatment with extract of *Musa paradisiaca* fruit significantly reduced the ulcer index in a dose dependent manner in which 0.44 ± 0.02 was recorded on 1000mg/kg of the extract. The observation was in concordance with that of the percentage ulcer inhibitory result which was also found to be dose dependent with 71.24% inhibition recorded on administration of 1000mg/kg of the extract. From the findings, it can be deduced that unripe *Musa paradisiaca* fruit have ulcer healing potential and should be recommended as an ideal diet for individuals on high risk category for gastric ulcer resulting from NSAID treatment.

KEYWORDS: *Musa paradisiaca*, Ulcer, Stomach, Aspirin.**INTRODUCTION**

Gastric ulcer is one of the most common kinds of peptic ulcer that occur in the stomach. [1] It is the disintegration of the stomach lining which interferes with the production of the mucous that coats the lining allowing gastric acid to come in contact with the stomach mucosa presenting symptoms such as abdominal discomfort, pain or nausea. [2] Its pathogenesis has continued to elude medical and traditional practitioners. However, it is believed that ulcers occur due to an imbalance between the aggressive factors (pepsin, gastric acid) and defensive factors (prostaglandins, mucin, bicarbonate etc.) which results in an interruption in the mucosal integrity. [3,4] Globally, gastric ulcer has become a major health problem with the potential for significant morbidity and mortality. [5] Over the years, conventional drugs such as the histamine receptor blockers and the proton pump inhibitors have been used in the treatment of gastric ulcer. Unfortunately, their usage is fraught with problems of side effects, relapse after treatment, aside the exorbitant cost that characterize them. [6,7]

Medicinal plants have contributed so much in the treatment and management of diseases such as ulcers. An example of medicinal plant includes *Musa paradisiaca* which is commonly known as plantain and belongs to the family Musaceae. It has been reported to have so many biological activities such as anthelmintic, [8] antitumor, [9] hypoglycaemic, [10] etc. Thus, the purpose of this study was to evaluate the ulcer healing potential of the ethanolic extract of unripe *Musa paradisiaca* fruits using rat model.

MATERIALS AND METHODS**Experimental Animals**

A total of twenty five (25) adult male Wistar rats weighing 200-220g were procured from the animal house of the Department of Anatomy, College of Health Sciences, Chukwuemeka Odumegwu Ojukwu University, Anambra State. The ethical committee of the College for animal care and use approved the study design in compliance with the National regulation for animal research. The animals were kept in standard cages under normal temperature (27-30°C) and were fed with

guinea feed and water *ad libitum*. The animals were acclimatized for a period of two weeks before administration of ethanolic extract of unripe *Musa paradisiaca* fruit that lasted for a period of 7 days.

Collection and Preparation of Unripe *Musa paradisiaca*

Unripe plantain (*Musa paradisiaca*) was obtained from okofia in Nnewi, Anambra state. The Unripe plantain peel was removed and the fruits washed in running tap water in a basin to remove dirt, cut into pieces and air dried under ambient temperature. It was then crushed into coarse powder using local grinder. 50g of the powder was dissolved in 1000ml of ethanol for 72 hours and then filtered using a clean white handkerchief. The filtrate was concentrated using a rotatory evaporator and further dried using a water bath into a gel-like form.

Acute Toxicity Test

This test was carried out using the method of Lorke.^[11] Three groups of three rats each were used in the first phase and were administered 10mg/kg, 100mg/kg and 1000mg/kg of *Musa paradisiaca* orally and were observed for mortality for 24 hours. In the absence of mortality, second phase commenced and the animals were divided into four groups of one animal each. Each group received 1200mg/kg, 1600mg/kg, 2900mg/kg and 5000mg/kg of *Musa paradisiaca* respectively. They were observed for 24 hours.

Induction of Ulcer

Aspirin produced by SKG-PHARM LIMITED was bought from a pharmaceutical shop. The animals in all groups were starved for 24 hours after which 300mg/kg body weight single dose of aspirin was administered orally to all treated groups except the normal control.

Experimental Design

The twenty five (25) animals were weighed and randomly allocated into five groups of five animals. The groups were designated as groups A, B, C, D and E. Each administration was given as follows:

Group A served as the normal control and were administered 2ml/kg of distilled water

Group B served as the negative control

Group C treated with 100mg/kg of ethanolic extract of unripe *Musa paradisiaca* fruit

Group D treated with 500mg/kg of ethanolic extract of unripe *Musa paradisiaca* fruit

Group E treated with 1000mg/kg of ethanolic extract of unripe *Musa paradisiaca* fruit

RESULTS

Table 1: Ulcer index and percentage inhibition of treated rats.

Treatment groups	Ulcer Index	% inhibition
Group A (Normal Control)	0	0
Group B (Negative control)	1.53 ± 0.46	0
Group C (Aspirin + 100mg/kg extract)	0.87 ± 0.51*	43.13
Group D (Aspirin + 500mg/kg extract)	0.85 ± 0.20 *	44.44
Group E (Aspirin + 1000mg/kg extract)	0.44 ± 0.02 *	71.24

The Administration was given orally between the hours of 6-8am daily and lasted for a period of 7 days. The animals were sacrificed by cervical dislocation 24 hours after the last administration and dissected. The stomachs were harvested, incised along the greater curvature to expose the walls. The contents were washed off and the walls viewed using a hand lens (x5) to determine the ulcer scores using the method of Raju *et al*^[12] and later fixed in 10% formal saline. The ulcerative lesions were counted and scored as follows:

Normal stomach..... (0)

Red coloration..... (0.5)

Spot ulceration..... (1)

Haemorrhagic streaks.... (1.5)

Ulcers..... (2)

Perforation..... (3)

The mean ulcer scores for each animal were expressed as ulcer index (UI).

The percentage inhibition was calculated according to the method of Hano *et al*^[13] using the formula

% Inhibition=

$$\frac{(\text{Mean ulcer index (control group)} - \text{mean ulcer index (Test group)}) \times 100}{\text{Mean ulcer index (control group)}}$$

Mean ulcer index (control group)

Tissue Processing

The tissues were processed for easy study under light microscope by passing them through the normal histochemical methods of fixation, dehydration, clearing, impregnation, embedding, sectioning, mounting, staining. Fixation was carried out in 10% formal saline and dehydration was carried out in ascending grades of alcohol and then cleared in xylene after which embedding in paraffin wax was carried out. 3-5µm of the sections was obtained using rotatory microtome. The sections were deparaffinised, hydrated and stained using haematoxylin and eosin (H&E) dye. They were later mounted using neutral dibutylphthalate xylene (DPX) medium for microscopic examination at x150 magnification.

Statistical Analysis

The results were expressed as mean ± SEM (standard error of mean). Data was analysed using Statistical Package for Social Sciences (SPSS) software (V20, USA) and one way analysis of variance (ANOVA) was used to determine the differences in mean of all parameters. Post-hoc Fisher's Least Significant Difference (LSD) multiple comparison was done and data were considered significant at p<0.05.

Values are expressed as Mean \pm SEM *= $p < 0.05$ compared to other groups

The ulcer healing effect of ethanolic extract of *Musa paradisiaca* fruit on aspirin induced ulcer is shown in Table 1. Oral administration of aspirin caused ulceration at the glandular region of the stomach. This was evidently shown on the negative control (1.53 ± 0.46), however, treatment with 100, 500 and 1000mg/kg b.w of *Musa paradisiaca* fruit extract caused significant

reduction in the ulcer index 0.87 ± 0.51 , 0.85 ± 0.20 and 0.44 ± 0.02 respectively. Similar observation was made on the ulcer inhibitory analyses of the extract carried out on the various groups of ulcerated rats on which the following results were found thus; 43.13%, 44.44% and 71.24% for groups C, D and E respectively.

Histopathological findings

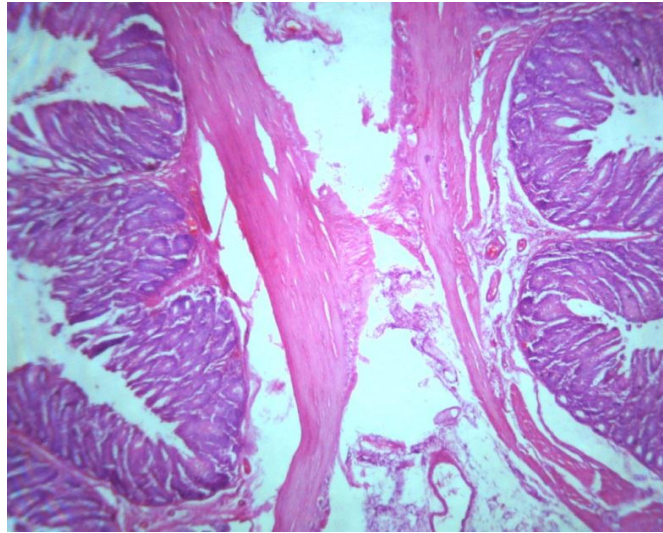


Plate A: Photomicrograph of the normal control section of the stomach of rats administered with 2ml/kg distilled water only showing normal cytoarchitecture.

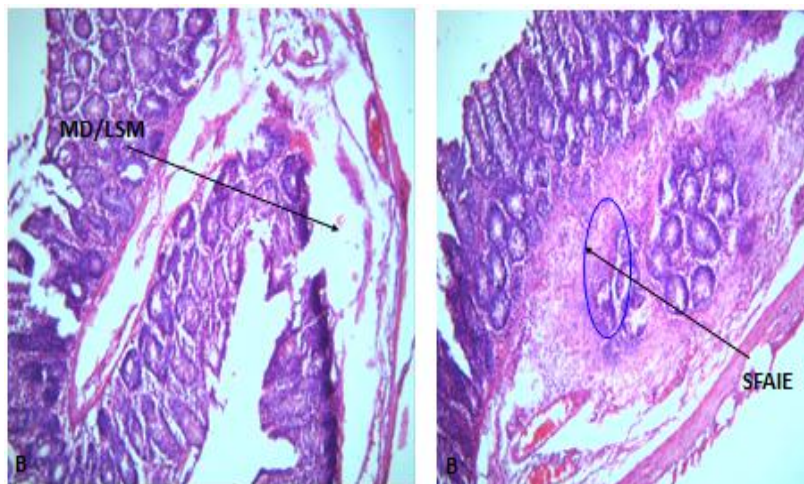


Plate B: Photomicrograph of stomach tissue of rats administered with 300mg/kg of aspirin only group showing severe focal area of inflammation exudates (SFAIE) growing within muscularis mucosa and moderate dilation and loss within the sub mucosa (MD/LSM).

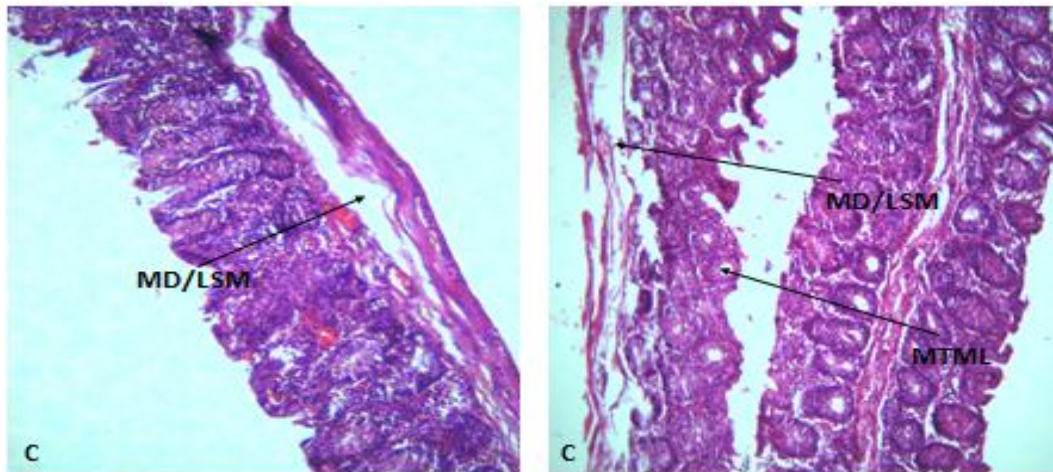


Plate C: Photomicrograph of stomach tissue of ulcerated rats treated with 100mg/kg *Musa paradisiaca* fruit extract showing mild healing with moderate thinning of the mucosa lining of (MTML) and mild dilation and loss within the submucosa (MD/LSM).

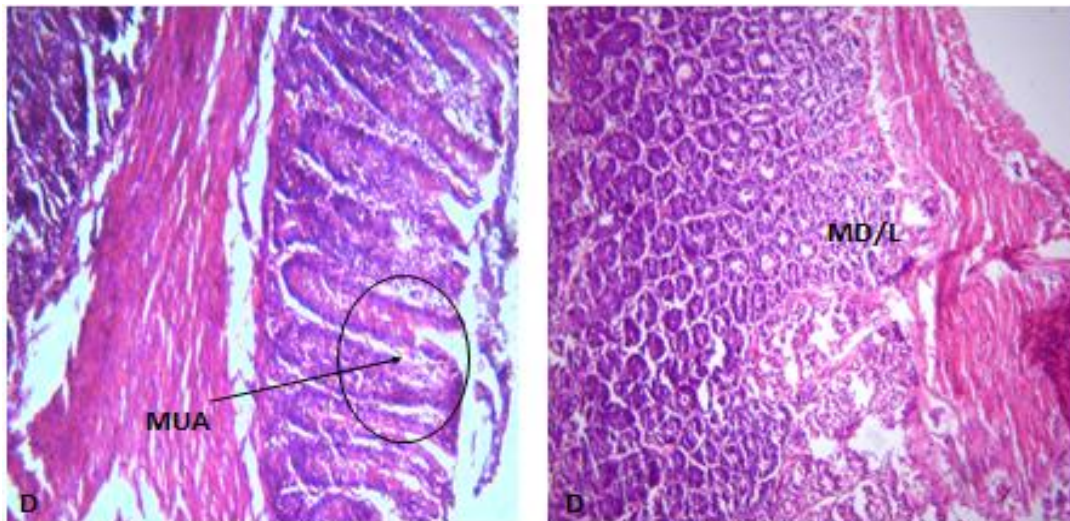


Plate D: Photomicrograph of stomach tissue of ulcerated rats treated with 500mg/kg *Musa paradisiaca* fruit extract showing moderate healing with mild dilation and loss within the submucosa (MD) and mild ulcerated area (MUA).

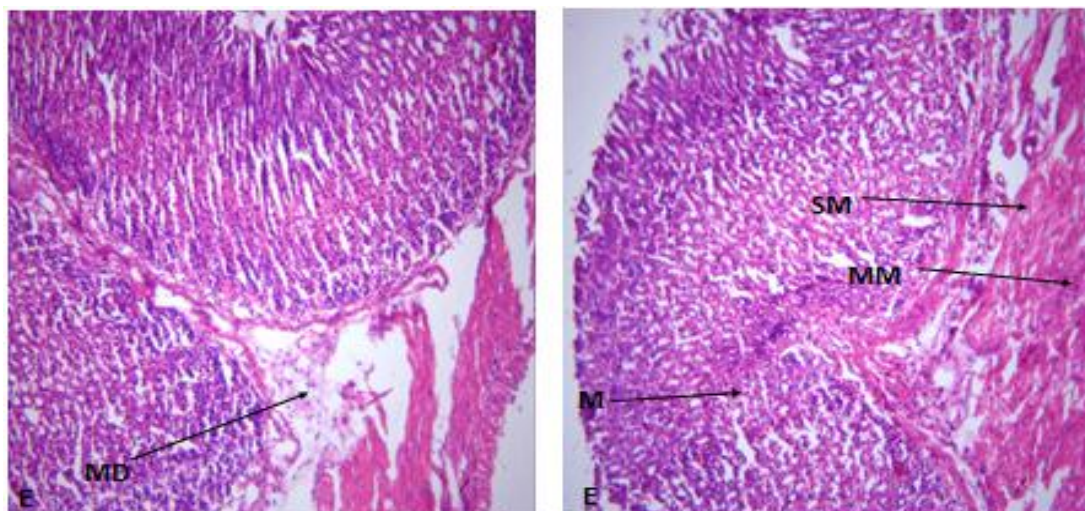


Plate E: Photomicrograph of stomach tissue of ulcerated rats treated with 1000mg/kg *Musa paradisiaca* fruit extract showing moderate healing with mild dilation within the submucosa (MD), normal mucosa (M), muscularis mucosa (MM) and submucosa (SM).

DISCUSSION

Medicinal plants have shown promising results in the management of peptic ulcer resulting in the current decline in the use of conventional drugs.^[14] This study was undertaken to evaluate the ulcer-healing effect of ethanolic extract of unripe *Musa paradisiaca* fruits on aspirin induced stomach ulcer. Oral administration of aspirin caused ulceration which was ameliorated following treatment with *Musa paradisiaca* fruit extract in a dose dependent manner. This finding is consistent with those of Enemchukwu *et al.*,^[15] Mbagwu *et al.*^[16] and Ezekwesili *et al.*^[17] who reported gastro-protective potential of extract of unripe plantain peel.

CONCLUSION

Nonsteroidal anti-inflammatory drugs (NSAIDs) are one of the most commonly prescribed classes of medication and has generally been used in the treatment of conditions such as analgesic, anti-inflammatory, osteoarthritis and rheumatoid arthritis. Unfortunately, the benefits associated with their consumption are challenged by numerous shortcomings. Thus, the outcome of this research has brought succour to this ugly situation as it is evident that unripe plantain fruit can salvage this seemingly hopeless situation and therefore should be recommended as an ideal diet for individuals on high risk category for gastric ulcer resulting from NSAID treatment.

ACKNOWLEDGEMENT

None.

REFERENCES

1. Najm WI. Peptic ulcer disease. Primary care, 2011; 38(3): 383-94.
2. Tarnawski A, Szabo IL, Husain SS, Soreghan B. Regeneration of gastric mucosa during ulcer healing is triggered by growth factors and signal transduction pathways. *Journal of Physiology*, 2001; 95: 337-44.
3. Raju D, Ilango K, Chitra V, Ashish, K. Evaluation of anti-ulcer activity of methanolic extract of *Terminalia chebula* fruits in experimental rats. *J Pharmacol Sci Res*, 2009; 1(3): 101-107.
4. Nartey ET, Ofosuhene M, Agbale C. Anti-ulcerogenic activity of the root bark extract of the African laburnum "*Cassia sieberiana*" and its effects on the antioxidant defense system in rats." *BMC Compl Alter Med.*, 2012; 12(247): 1-9.
5. Bhattacharjee M, Bhattacharjee S, Gupta A, Banerjee RK. Critical role of an endogenous gastric peroxidase. *Biochem Pharmacol.*, 2002; 37: 271-80.
6. Srikanta BM, Siddaraju MN, Dharmesh SM. A novel phenol-bound pectic polysaccharide from *Decalepis hamiltonii* with multi-step ulcer preventive activity. *World J Gastroenterol.*, 2007; 13(39): 5196-207.
7. Muralidharan P and Srikanth J. Antiulcer activity of *Morinda citrifolia* (Linn) fruit extract. *J Sci Res.*, 2009; 1(2): 345-352.
8. Krishna VV, Girish-Kumar K, Pradeepa K, Santosh-Kumar SR, Vijay K. Anthelmintic activity of *Musa paradisiaca* (L.) puttable. *Int J Pharm Sci Drug Res.*, 2013; 5(2): 67-69.
9. Kazi A, Urbizu DA, Kuhn DJ, Acebo AL, Jackson ER, Greenfelder GP, Kumar NB, Dou QR. A natural Musaceas plant extract inhibits proteasome activity and induces apoptosis selectively in human tumor and transformed, but not normal and non-transformed cells. *Int J Mol Med.*, 2003; 12(6): 879-887.
10. Ekpo B, Ajibesin K, Eseyin O, Danladi B. Evaluation of hypoglycemic action of *Musa paradisiaca* in rats. *Int J Res Ayurv Pharmacol.*, 2011; 2(2): 498-501.
11. Lorke, U.C. Determination of lethal dose of xenobiotics in experimental animals. *Nature*. 1983; 45: 264-266.
12. Raju D, Ilango K, Chitra V, Ashish K. Evaluation of anti-ulcer activity of methanolic extract of *Terminalia chebula* fruits in experimental rats. *J Pharmacol Sci Res.*, 2009; 1(3): 101-107.
13. Hano J, Bogajski J, Danek L, Wantuch C. The effect of neuroleptic development of gastric ulcers in rats exposed to restraint cold stress. *Journal of Pharmacology*, 1976; 32(54): 23-25.
14. Goel RK and Sairam K. anti-ulcer drugs from indigenous sources with emphasis on *Musa sapientum*, *Asparagus racemosus* and *Zingiber officinale*. *Indian J Pharmacol.*, 2002; 34: 100-10.
15. Enemchukwu BN, Onyedima EI, Ubaoji KI, Ngele KK. Anti-ulcer effect of aqueous extract of unripe plantain peels on male wistar (albino) rats. *Biotechnol Indian J.* 2014; 9(12): 511-515.
16. Mbagwu H, Jackson C, Ekpo M, Okopedi E, Anah V, Ugwu C. Gastro-protective effects of ethanolic leaf extract of *Musa paradisiaca* L. (Musaceae) in rats. *J Chem Pharmacol Res.*, 2011; 3(3): 322-327.
17. Ezekwesili CN, Ghasi S, Adindu CS, Mefoh NC. Evaluation of the anti-ulcer property of aqueous extract of unripe *Musa paradisiaca* Linn. Peel in wistar rats. *Afr J Pharm Pharmacol.*, 2014; 8(39): 1006-1011.