

**SUBACUTE SCLEROSING PANENCEPHALITIS (SSPE) WITH ATYPICAL ONSET****Dr. Suraj Rajesh Sethiya*¹, Dr. Fiona Mahapatro², Dr. Sanjiv Kale³ and Dr. Chetan Vispute⁴**¹Resident, Department of Psychiatry, Dr. D.Y. Patil Hospital and School of Medicine, Sector-5, Nerul, Navi Mumbai, Maharashtra.²Professor, Department of Psychiatry, Dr. D.Y. Patil Hospital and School of Medicine, Sector-5, Nerul, Navi Mumbai, Maharashtra.³HOD and Professor, Department of Psychiatry, Dr. D.Y. Patil Hospital and School of Medicine, Sector-5, Nerul, Navi Mumbai, Maharashtra.⁴Assistant Professor, Department of Psychiatry, Dr. D.Y. Patil Hospital and School of Medicine, Sector-5, Nerul, Navi Mumbai, Maharashtra.***Corresponding Author: Dr. Suraj Rajesh Sethiya**

Resident, Department of Psychiatry, Dr. D.Y. Patil Hospital and School of Medicine, Sector-5, Nerul, Navi Mumbai, Maharashtra.

Article Received on 10/10/2018

Article Revised on 31/10/2018

Article Accepted on 21/11/2018

ABSTRACT

Subacute sclerosing panencephalitis (SSPE) is a common and serious disease of the central nervous system (CNS), and is caused by a mutant measles virus.^[2] Catatonia is a neuropsychiatric syndrome characterized by mutism, stupor, refusal to eat or drink, posturing, and excitement or hypokinesia.^[6] Medical, Neurological disorders and Neuropsychiatric disorders like Schizophrenia, affective disorders can present with Catatonia. We hereby describe a case of 22yr old female, who presented with catatonia but eventually developed the typical symptoms of SSPE highlighting the importance of keeping in mind the differential diagnosis for all medical conditions.

KEYWORDS: Subacute sclerosing panencephalitis, SSPE, Catatonia, Brief Psychotic Disorder, EEG findings, abnormal movements, rare case.

INTRODUCTION

Subacute sclerosing panencephalitis is a common and serious disease of the central nervous system and is caused by a mutant measles virus.^[2] SSPE is a slow virus infection producing inflammatory changes of the brain and subsequently death of cortical neurons.^[5] A chronic brain disease of children and adolescents that occurs months to often years after an attack of measles, causing convulsions, motor abnormalities, mental retardation and, subsequently it can be fatal.^[3] One in about 1,400 children who get measles before the age of 5yrs. may eventually develop SSPE.^[4] The initial symptoms include mild intellectual deterioration and behavioral changes without any apparent neurological signs or findings. The clinical features of SSPE progress gradually to generalized tonic-clonic seizures, disturbances in motor function and development of periodic stereotyped myoclonic jerks involving the head and subsequently trunk and limbs. Myoclonus can present as a difficulty in gait, periodic dropping of the head, and falling while few other patients may develop ataxia, dystonia, and dyskinesia.

CASE REPORT

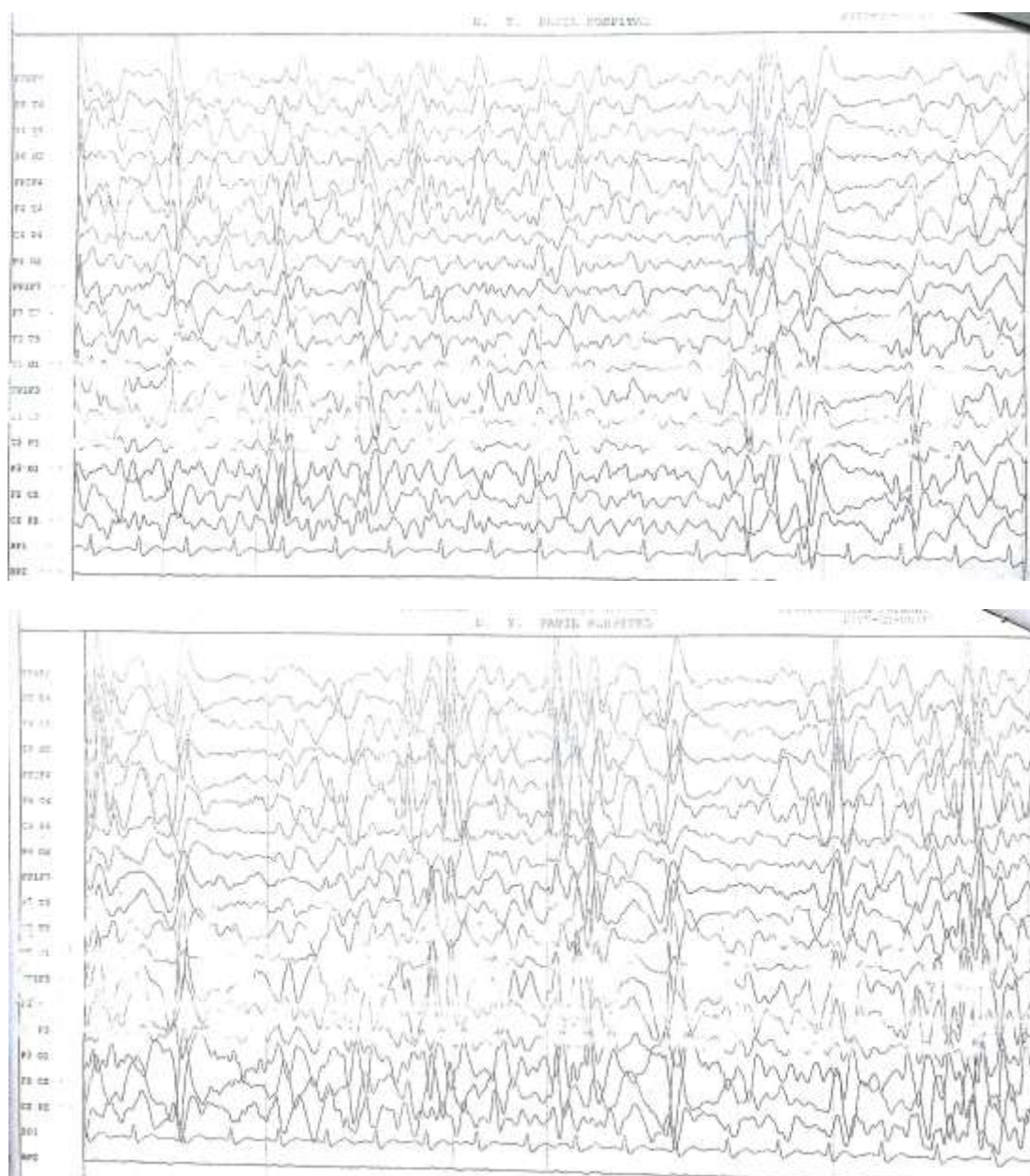
A 22-year-old female presented with subacute onset of symptoms over 3 months characterized by muttering, gesticulating and smiling inappropriately to self on

occasions. She was withdrawn to self and was minimally communicative with her family members as well as neighbors. Gradually her self-care also deteriorated, including inability to take care of her menstrual hygiene. She was found having jerky movements of her entire left hand, repeatedly. When questioned regarding any of these behaviors, she would only respond with a silly smile. This silly smile would also be explicated when her husband would talk to her regarding a specific street food item. Then, twenty days prior to being brought to the hospital, she stopped all communication, would always lie supine in the bed for hours and require assistance in all day-to-day activities. The patient also had history of one episode of generalized tonic-clonic seizure, a month prior to admission to the hospital. Patient was treated on outpatient department as relatives refused admission. Her symptoms improved gradually after 3 weeks of pharmacotherapy with Tablet olanzapine 2.5 mg OD and tablet clonazepam 0.25 mg OD. Thereafter she was noncompliant to medications for 2 months and her disease progressed gradually and presented with catatonic symptoms on admission. In view of catatonic symptoms like mutism, withdrawn behavior, posturing, psychomotor retardation, injection Lorazepam was administered intravenously in divided doses along with injection Haloperidol and Promethazine intramuscularly. Her catatonic symptoms improved immediately next day,

and patient was communicative with the relatives and started accepting food orally. However, the improvement in the catatonic symptoms was short lasting as the patient deteriorated neurologically. She developed gait disturbances, myoclonus and altered sensorium.

The patient underwent multiple investigations including computed tomography (CT) scan, magnetic resonance imaging (MRI) scan, and electroencephalogram (EEG). Her CT scan and MRI Brain were normal. However,

EEG recorded typical Burst Suppression pattern, which is suggestive of SSPE. Hence, a neurology reference was sought for, wherein she was provisionally diagnosed as having SSPE. Antimeasles antibody titers were performed which were found to be increased i.e. IgG CSF 9.68mg/dl (normal range 0.0-3.4mg/dl), IgG-Albumin ratio (CSF)=1.010 (normal range 0.09-0.25), CSF IgG index(calculated)= 2.760(0.28-0.66). Based on these findings, a diagnosis of SSPE was confirmed. After 8-9 days of treatment, the patient succumbed to illness.



DISCUSSION

SSPE

SSPE a unique slow viral disease affecting central nervous system and is the most fatal sequelae of measles virus. This neurodegenerative disorder has usual age of onset between 5 and 12 years of age. As per a study by L K Prashanth *et al.* the incidence of adult onset SSPE has been reported to vary between 1–1.75% and 2.6%.^[7]

A similar study conducted by Singer *et al* suggested that adult onset SSPE patients acquire measles either at an early age (<3 years) or at an unusually late age (>9 years). However, there are certain differences between the clinical manifestations of childhood onset SSPE and adult onset SSPE.

SSPE has progressive downhill course initially presenting with sudden behavioral changes, gait imbalance, psychomotor retardation, seizures, chorioretinitis, and involuntary movements^[3]. Myoclonic jerks, spasms, and severe physical and cognitive impairment develop gradually with the disease progression.^[1] Psychiatric manifestations of SSPE that have been reported include emotional lability, personality changes, cognitive impairment, depression, anxiety, mania and rarely psychoses.^[3,4] In a case reported by Parmar *et al.* recently, SSPE had developed with apparent manifestations of catatonia and psychosis which led to delay in diagnosis.^[8] Thus, the difficulty in establishing a diagnosis of SSPE arises because the presenting features are those of acute psychosis and catatonia; but it is only thorough investigations that SSPE can be established as a diagnosis.

The course and prognosis of adult onset SSPE is not clearly known due to the dearth of reports in the literature. It is believed, however, that SSPE has a belligerent course in adults.^[9]

Tan *et al* reported that six out of seven patients died within 1 year of onset of symptoms. They stated that mortality of patients with SSPE increases with increasing age of onset.^[9] Singer *et al* observed a mean survival period of 24 months (range: 8 months to 6 years) with three patients surviving for more than 3 years. They stated that patients with adult onset SSPE have a higher rate of spontaneous remission and favorable response to disease modifying agents.^[10]

CONCLUSION

It is indeed a diagnostic dilemma when a patient presents with features resembling acute psychosis and catatonia. Without rushing to establish a diagnosis as soon as the patient arrives, a detailed history is essential encompassing all aspects in total. Not just that, patient's response to given initial treatment should also be taken into consideration when there is a diagnostic dilemma. The patient should also be thoroughly investigated, to have a 'gestalt' approach to the entire presentation. Like the given case, the patient might present with psychiatric features like psychosis and catatonia; however, it is only through a detailed history and thorough investigations that underlying serious medical conditions like SSPE can be diagnosed and treated.

SSPE is a devastating illness for families of the affected children. In a few, the disease can progress very rapidly and lead to death within a few months. So far available treatments are disappointing. In developing countries, the situation is grim. SSPE is still very frequently encountered. Combination of Isoprinosine and intraventricular alpha-interferon is unaffordable. Novel therapies, like recombinant adenovirus expressing the small interfering RNA inhibiting replication of SSPE virus, do provide hope for the future. Vaccination against

measles remains the most effective strategy against SSPE.

REFERENCES

1. Bellini WJ¹, Rota JS, Lowe LE, Katz RS, Dyken PR, Zaki SR, Shieh WJ, Rota PA. Subacute sclerosing panencephalitis: more cases of this fatal disease are prevented by measles immunization than was previously recognized. *J Infect Dis.*, Nov 15, 2005; 192(10): 1686-93. Epub 2005 Oct 12.
2. R.K. Garg B. Karak A.M. Sharma, Subacute Sclerosing Panencephalitis, *INDIAN PEDIATRICS*, April, 1998; 35.
3. <https://www.medicinenet.com/script/main/art.asp?articlekey=6341>
4. <https://www.webmd.com/children/news/20161028/dreadly-measles-complication-may-be-more-common-than-believed#1>
5. Ravindra Kumar Garg Subacute sclerosing panencephalitis *J Neurol*, 2008; 255: 1861–1871 DOI 10.1007/s00415-008-0032-6
6. NY-Presbyterian Hospital/Weill Cornell Medical Center, Department of Psychiatry, 525 East 68th St., Box 140, New York, NY 10065, USA. jed7002@med.cornell.edu *J Neuropsychiatry Clin Neurosci*, Fall, 2009; 21: 4.
7. L K Prashanth, A B Taly, V Ravi, S Sinha, and G R Arunodaya Adult onset subacute sclerosing panencephalitis: clinical profile of 39 patients from a tertiary care centre *J Neurol Neurosurg Psychiatry*. 2006 May; 77(5): 630–633. Published online, 2006 Feb 9. doi: 10.1136/jnnp.2005.085829
8. Arpit Parmar, Rajeev Ranjan,¹ and Rajesh Sagar Subacute sclerosing panencephalitis presenting with isolated positive psychotic and catatonic symptoms *Indian J Psychol Med.*, Jul-Aug, 2017; 39(4): 534–536. doi: 10.4103/0253-7176.211756.
9. Singer C¹, Lang AE, Suchowersky O. Adult-onset subacute sclerosing panencephalitis: case reports and review of the literature. *Mov Disord*, May, 1997; 12(3): 342-53.